

Sclerodermatomyositis

M Febyani,¹ H Purbo D,¹ L Hamijoyo,² E Sutedja,¹ O Suwarsa¹

¹ Department of Dermatology, Padjadjaran University School of Medicine/ Hasan Sadikin Hospital, Bandung;

² Division of Rheumatology, Department of Internal Medicine, Padjadjaran University School of Medicine/Hasan Sadikin Hospital, Bandung

The classification of rheumatic diseases is still challenging due to several reasons. First, those diseases have several differential clinical features, which giving overlap symptoms. Second, the etiopathogenesis of those diseases remains elusive. Diagnosis of overlap syndrome is made when there are more than one well-defined connective tissue diseases in one patient, which may develop simultaneously or sequentially.^{1,2} The prevalence of overlap syndrome among autoimmune diseases is 25%.²

The term sclerodermatomyositis or scleromyositis is used to describe an overlap syndrome in patients with scleroderma and dermatomyositis/polymyositis (DM/PM).^{2,3,4} Sclerodermatomyositis usually affects adults, and it is rarely found in children.⁴ The clinical features of this syndrome are myalgia or myositis, arthralgia, scleroderma-like skin changes, Raynaud's phenomenon (RP),^{2,3} interstitial lung disease, calcinosis,³ mask-like facies, dysphagia or esophageal dysmotility,⁴ as well as the presence of specific antibody Pm/ScI.² Skin manifestations as the part of dermatomyositis include periorbital erythema and Gottron's papules.³

We report this case due to its very rare occurrence. According to medical records in the Department of Dermatology as well as Rheumatology at Hasan Sadikin Hospital, Bandung, this is the first case recorded in the last 10 years.

CASE REPORT

An 18-year-old, single, Sundanese female, came to our institution with chief complaint of rashes on her arms, hands, legs, and abdomen.

Since 2 years prior to this visit, she has had complaint of joint pain on both elbows, with rashes on the surface of her knees and elbows, as well as photosensitivity and oral ulcers. At that time, his physician considered systemic lupus erythematosus (SLE) as the cause of her symptoms. Laboratory test results were normal, except for leucopenia (white blood cell count of $4 \times 10^3/\text{mm}^3$). At that time, the patient also had negative antinuclear antibody (ANA) and anti-double-stranded DNA (anti-dsDNA) tests. She was given nonsteroidal anti-inflammatory drugs (NSAIDs) and subsequently showed improvement.

One year prior to admission, she started to have difficulty swallowing foods and liquids, also accompanied with rough skin on her face, rashes on her eyelids, face, chest and back, as well as

photosensitivity. Afterwards, she developed erythematous rashes on her arms, abdomen and both legs, accompanied with skin tightening. She also had alopecia and weight loss.

Physical examination on admission at our institution revealed normal vital signs. There were heliotrope rashes on her palpebras, and Gottron's papules as well as Gottron's sign over the surface of her metacarpophalangeal joints and elbows. She had rashes on her neck (shawl sign, V-sign), sclerodactyly, and muscular atrophy of her upper extremities. Rodnan skin score was 19. On palpation, the skin on her abdomen, arms, hands, legs, and feet felt tight and taut. She had difficulty raising her arms and step on ladders or stand up from sitting position.

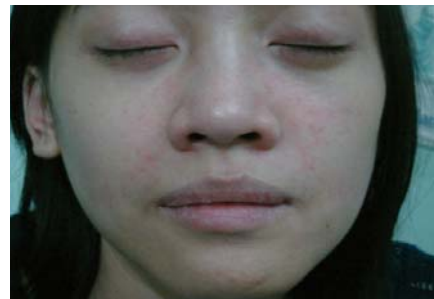

Figure 1 Heliotrope on patient's eyes

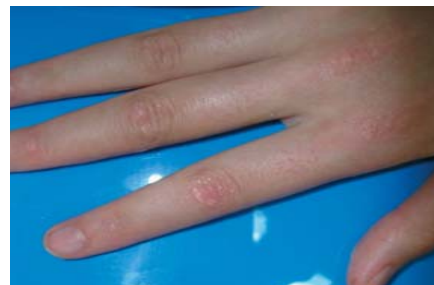

Figure 2 Sclerodactyly and Gottron's papules on PIP and DIP surface

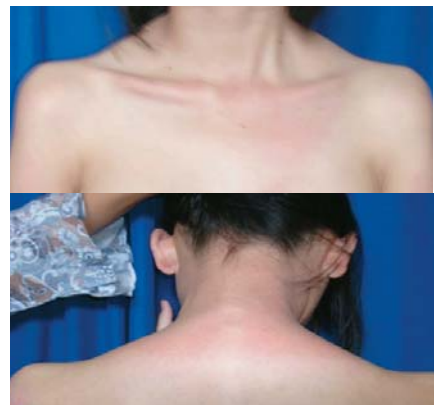

Figure 3 V sign and shawl sign

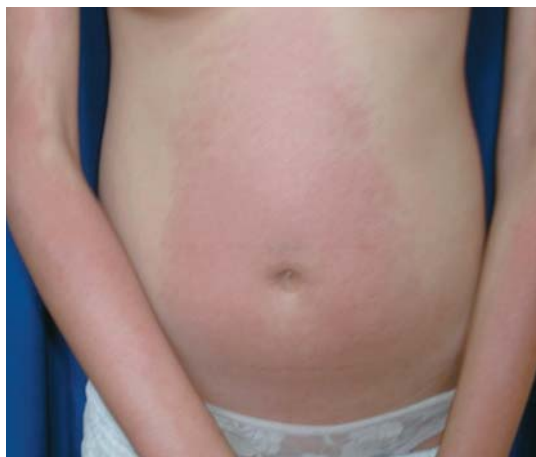

Figure 4 Rashes on the patient's arms and body

Her laboratory results were normal except for mild increase of lactate dehydrogenase (LDH) (456 U/L) and creatine kinase (CK) (20 U/L) as well as positive ANA test with speckled pattern. Anti-RNP was negative, neither anti-Jo-1 and anti-Scl-70. Skin biopsy of her femoral area revealed stratified squamous epithelium with atrophy and mild keratinization, with liquefactive degeneration of the basal layer in the center of the specimen. In dermis, a number of capillary arteries showed wall-thickening and fibrinoid degeneration. Masson's trichrome and van Gieson's stain showed thickening of some of the collagen fibrils. Direct immunofluorescence of skin biopsy specimen showed no immunoglobulin (IgG, IgA, IgM), complement component 3 (C3), or fibrinogen deposition. Electromyography (EMG) was also performed in this patient, but the result was within normal limit.

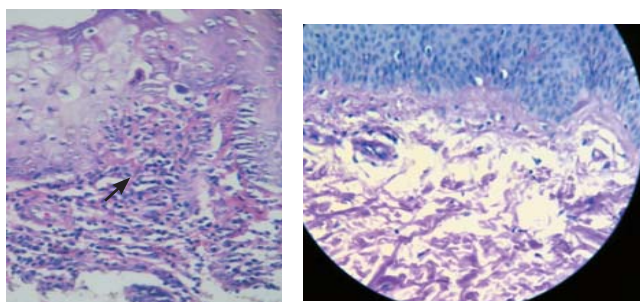


Figure 5 Histopathological specimen from patient's skin, showing liquefactive degeneration (arrow)

The patient was diagnosed sclerodermatomyositis and was given methylprednisolone 0.8 mg/kg body weight daily, methotrexate (MTX) started 7.5 mg weekly, folic acid 1 mg daily, urea and mometasone cream, as well as sunscreen cream. She was referred to the Department of Medical Rehabilitation and Department of Clinical Nutrition for further assistance with her condition.

On the follow-up at day 18, the skin rashes had reduced but the weakness and skin tautness remain. On day 43, the patient began to be able to climb stairs and rise from sitting position without help, although she still had difficulty to stand up from squatting position. The skin lesions also began to diminish, except for the skin tautness and Gottron's papules.

Methylprednisolone was thus tapered down.

On day 57, CK was 32.1 U/L and LDH decreased to 434 U/L. On day 80, her condition continued to improve, Rodnan skin score was 10, and the patient could stand up from squatting position.

DISCUSSION

Dermatomyositis is an idiopathic inflammatory myopathy characterized by proximal muscle weakness and skin eruption.⁵ When the skin lesions are absent, the disorder is termed polymyositis. Involvement of proximal muscles is the characteristic feature of this disease.^{6,7} There are several types of dermatomyositis known: classic, amyopathic, and hypomyopathic dermatomyositis. The term classic dermatomyositis is used when myositis is accompanied with proximal muscle weakness and characteristic skin lesions. In amyopathic dermatomyositis there are skin lesions consistent with dermatomyositis which have been present for at least 6 months, without proximal muscle weakness or serum muscle enzymes abnormality. In hypomyopathic dermatomyositis, there is subclinical myositis found in laboratory examination.^{7,8,9}

Creatine kinase level is important in myositis cases,^{8,9,10} because of its relative sensitivity and specificity in assessing the extent of muscle fiber damage.^{7,10} In 80-90% cases of myositis, CK level are usually elevated in initial measurement, but subsequently become normal due to the decrease in muscle mass or inhibition to CK activity.¹⁰

Measurement of other enzymes, such as aldolase, aspartate and alanine aminotransferase, and LDH can also help in making the diagnosis of myositis, particularly in patients with active disease and normal CK level.^{9,10} When measurement of these enzymes is performed, it is important to consider that conditions such as liver diseases may also elevate the level of these enzymes.¹⁰

Erythrocyte sedimentation rate (ESR) may be elevated; however, it is not usually associated with disease activity. Elevation of rheumatoid factor (RF) may be encountered in 20% cases of dermatomyositis.⁷ Electromyography is a sensitive, but not specific method in diagnosing dermatomyositis;¹¹ as many as 10% of patients may have normal results.⁷

In 60% of cases, skin lesions and proximal muscle weakness may occur simultaneously. Skin lesions are often accompanied by itching or burning sensation, and it may be triggered by exposure to sunlight or ultraviolet light.⁷ The predominant skin lesions in dermatomyositis are symmetric, confluent, purplish erythematous macules over the extensor surface of fingers, dorsal aspects of hand, arm, deltoid area, back, and neck (shawl sign), in a "V"-like distribution over the anterior neck and upper chest (V-sign), and middle part of the face, periorbital area, forehead, and scalp.^{6,11}

Characteristic lesions are often found around the eyes, appearing as a pink, scaly patch with itching, swelling, and violaceous change (heliotope rash), or bulla.⁶ Other reported skin lesions in dermatomyositis include urticaria, photosensitivity, erythema nodosum, erythema multiforme, keratosis follicularis, hypertrichosis, livedoreticularis, hyperhidrosis, psoriasiform eruption, pitting nail, and ulcer.¹²

Exfoliative dermatitis may also occur in dermatomyositis, but rare. Diffuse alopecia may occur on scalp.^{9,12} Hyperpigmentation may occur later in the course of the disease.^{8,12} Recurrent aphthous stomatitis was reported in one case of sclerodermitis.¹³ Periungual telangiectasia that is related to cuticular dystrophy is a characteristic lesion.¹¹ In patients with positive anti-synthetase antibody, there may be hyperkeratotic lesion, fissures, and linear hyperpigmentation on the palmar surface of the hand, which termed mechanic hands.^{9,12}

In 20% cases, dermatomyositis is accompanied by other connective tissue diseases (overlap syndrome); thus, it is important to look for characteristic symptoms of other connective tissue diseases.^{7,11} Dermatomyositis commonly overlaps with scleroderma, and it is called sclerodermatomyositis.⁶

Early in the course of the disease, weakness occurs in muscles on shoulder and waist; therefore, the patients had difficulty in performing specific movements such as moving arms upward, or stand up from sitting position. Muscle weakness may be accompanied by muscle pain and tenderness.⁷ Patients with dermatomyositis often complains malaise and fatigue. Myopathy affects proximal muscle groups, particularly triceps and quadriceps,¹¹ with symmetrical distribution.^{6,11} Later in the course of the disease, all muscle groups may be affected.¹¹ Other systemic disorders that also occurred in dermatomyositis were calcinosis of deep fascia and muscles,^{11,12} disorder of the lung and heart, arthritis,¹¹ kidney, gastrointestinal system,^{7,11} eyes, and malignancy.^{7,12}

In 1972, Sharp et al introduce the term "mixed connective tissue disease" (MCTD), a disorder characterized by combination of two or more autoimmune diseases: SLE, progressive systemic sclerosis (PSS), dermatomyositis, or polymyositis.^{14,15} The main symptoms of MCTD include Raynaud's phenomenon (93% of cases), arthralgia/joint involvement (93%), edema of the fingers and hand (71%), lymphadenopathy (71%), myositis/muscle involvement (50%), serositis (29%), hepatomegaly (21%), and splenomegaly (21%). Other symptoms include esophageal reflux, sclerodactyly, and lung involvement.^{14,16} Diagnosis of MCTD should be considered when there are clinical presentation of SLE, PSS, dermatomyositis, or polymyositis in one patient.^{16,17} Characteristic serological findings are high ANA titer (usually more than 1:1000) with speckled pattern, anti-RNP, and anti-U1RNP antibodies.^{14,15} Antibodies such as anti-dsDNA, anti-SSa, anti-SSb, or anti-Smith are not usually found in MCTD. Although our patient had high titer of ANA, the diagnosis of MCTD can be excluded since the anti-RNP antibody was negative.

Scleroderma or systemic sclerosis (SSc) is a chronic multisystem disorder, characterized by sclerosis of connective tissue,^{18,19} vascular disorder, and involvement of visceral organs.¹² The diagnostic criteria for SSc have been made by the Subcommittee for Scleroderma Criteria of the American Rheumatism Association and have been widely used, in which, for the diagnosis to be made, the patient must have (1) proximal scleroderma on the fingers, extremities, face, neck or the trunk; or (2) at least 2 of the minor criteria: (a)

sclerodactyly, (b) digital pitted scarring, (c) bilateral basal pulmonary fibrosis.¹² These criteria have a sensitivity and specificity of 97% and 98%, respectively.^{46,12}

Systemic sclerosis is classified into localized cutaneous SSc (lcSSc) and diffuse cutaneous SSc (dcSSc). The difference between the two type lies in the extent of skin involvement and other clinical and immunological presentations.^{6,12}

Clinical manifestations in lcSSc are marked by history of Raynaud's phenomenon (in 1 to 10 years) before tightening of the skin on the distal extremities, without involvement of the trunk. In lcSSc, the classic CREST syndrome may also be found: calcinosis cutis, Raynaud's phenomenon, esophageal dysfunction, sclerodactyly, and telangiectasia.^{18,20} Visceral organ involvement include pulmonary hypertension, pulmonary fibrosis, and gastrointestinal system. Vascular involvement include ischemia and ulceration of the fingers, and gangrene that may result in autoamputation.^{18,19}

The patient in this case report was diagnosed with sclerodermatomyositis based on history of pain in both elbows, with difficulty in raising the arms and standing up from sitting position. Those complaints were also accompanied by skin changes on face, elbows, hands, abdomen, knees, and legs, which were characteristics of dermatomyositis. There were also history of dysphagia, difficulty opening the mouth, Raynaud's phenomenon, and tight and hard skin on arms and legs, which support the diagnosis of scleroderma.

On physical examination, we found skin lesions that support the diagnosis of dermatomyositis: heliotrope rash, Gottron's papules, and shawl sign. Those skin lesions were also accompanied by muscle atrophy, alopecia, as well as pain and stiffness of the proximal muscles. Physical examination that support the diagnosis of scleroderma were Raynaud's phenomenon, sclerodactyly, and skin hardening of the arms, hands, fingers, abdomen, and legs. The level of LDH in the patient was increased, with normal level of other muscle enzymes.

The erythematous lesion and edema in dermatomyositis commonly exhibit nonspecific histopathological appearance.^{12,21} The histopathological findings in dermatomyositis include epidermal atrophy, basement membrane degeneration, vacuolar changes of basal keratinocytes, and dermal changes, such as interstitial mucin deposits with rare lymphocyte infiltration.^{6,11,21}

The epidermis in SSc may appear normal, atrophic, or thickened. The dermis may appear thicker and consist of dense collagen bundles that can be visualized by trichrome staining.²²

The histopathological examination of the patient's skin revealed atrophy, mild keratinization, liquefactive degeneration of the basal layer in the center, and thickening of the basement membrane. This appearance could also be found in dermatomyositis. Trichrome staining did not show thickening of collagen.

Positive ANA may be found in 50-80% of dermatomyositis cases, particularly in patients with overlap syndrome.^{6,10} Common ANA patterns were speckled and nucleolar pattern.⁷ Autoantibodies in patients with dermatomyositis are divided into 2 groups: myositis-specific and myositis-associated

antibodies. The first group is found in <50% of patients and has a worse prognosis. Antibodies such as anti-histidyl-tRNA synthetase (anti-Jo-1) belong to this group. The second group is found in 30-40% of patients, which include anti-Ro/SSA and anti-U1RNP. Anti-PM/Scl, anti-Ku, and anti-U2RNP antibodies are found in patients with overlap of dermatomyositis and scleroderma.⁷ Anti-PM/Scl is found in 24% of dermatomyositis cases, but it could also be found in 8% of polymyositis cases and 3% of scleroderma cases.¹⁵ Positive anti-PM/Scl antibodies is often associated with nucleolar pattern of ANA.⁴

More than 90% of patients with scleroderma have positive ANA.²³ Positive ANA with nucleolar pattern is specific for scleroderma; however, speckled pattern can also be found, as well as in patients with CREST syndrome,⁶ dermatomyositis, or MCTD. Scl-70 autoantigen may be found in 70% of dcSSc. Anticentromere antibodies may be found in 50-96% of lcSSc patients.²⁴

The patient had positive ANA with speckled pattern; however, ANA profile did not show significant increase in the level of autoantibodies.

There is a marked difference in terms of response to therapy between muscle and skin involvement.^{5,11} Skin manifestations in dermatomyositis are usually more difficult to treat. The American Academy of Dermatology (AAD) recommend aggressive protection against sunlight with physical barrier, sunscreen, and topical corticosteroid.^{1,5} Because patients with dermatomyositis usually have xerosis, the use of moisturizers will also be beneficial. Topical antipruritics may also given relieve to itchy skin lesions.^{7,8,25} Patients are advised to use sunscreen with high SPF (>30) daily, avoid direct exposure to sunlight, cold temperatures, stress, and perform regular exercise to maintain joint mobility.⁵

Systemic corticosteroid is the therapy of choice in dermatomyositis, given as daily-dose prednisone or pulse-dose methylprednisolone.^{24,25,26} The AAD recommends systemic corticosteroid for early control of muscle disease with a dose of 0.5-1.5 mg/kg/day. After control of the disease is achieved, the dose could be tapered down, usually every 4 to 6 weeks.^{5,6} As many as 50-75% of dermatomyositis cases that are given corticosteroid showed complete remission.²⁵

Other immunosuppressant drugs such as MTX, azathioprine, cyclophosphamide, cyclosporine,^{6,25,26} and mycophenolate mofetil²⁶ can be given to control the disease and accelerate the tapering of corticosteroid.²⁵ A study that compared MTX and azathioprine showed no difference in efficacy between the two drugs, although the side effects of MTX was more tolerable.²⁶

For dermatomyositis, MTX may be given early in the course of the disease or for refractory cases.^{5,9} It may also be given to patients with SSc.^{18,27} MTX is given when there is inadequate response to prednisone,⁵ but it may also be given in combination with prednisone as first-line therapy in severe myositis.²⁶ Weekly dose of MTX is usually 7.5-25 mg orally.⁷ Approximately 70-77% of patients who need adjuvant therapy showed response to MTX therapy.⁵ Before starting initial therapy of MTX, thorough examination of the patient should be conducted, including routine laboratory examination

that comprise of complete blood count and liver and kidney function test.²⁷ MTX may reduce diffuse skin hardening in scleroderma, but further studies are needed to confirm this.⁶

Bed rest is advised to patients with dermatomyositis who have severe inflammation; however, exercise and physical therapy are also needed as part of rehabilitation and therapy of dermatomyositis. In the evaluation, clinician should make a decision concerning the need of exercise program in each patient. The program should be arranged by physiotherapist, starting from passive and continued to active exercise. After the improvement of clinical condition, passive therapy can be continued with active therapy.^{5,25}

Our patient was advised to avoid exposure to cold and sunlight. Topical therapies given were moisturizer, sunscreen, and topical corticosteroid. Systemic therapies were systemic corticosteroid given in 0.8 mg/kg prednisone-equivalent dose and MTX with a dose of 7.5 to 10 mg per week.

The mortality rate of dermatomyositis ranges between 8.9 to 52 percent, depending on the variation of the clinical presentation.⁵ Mortality in dermatomyositis is mainly caused by malignancy,⁶ ischemic heart disease, and lung disease.^{6,7,12} Sclerodermatomyositis usually has better prognosis.^{4,7} In the last two decades, the mortality rate of dermatomyositis has been declining, owing to the use of corticosteroid and other immunosuppressant drugs;⁷ however, the risk of malignant degeneration is still high, particularly in the first 5 years since diagnosis.²⁸ Most patients showed good response to therapy, but in some cases there may be residual muscle pain¹² or muscle weakness²⁹ despite the inactivity of the disease. Relapse may occur at any time, including when the steroid dose is being tapered.^{25,29}

SUMMARY

We have reported a rare case of sclerodermatomyositis, an overlap syndrome between scleroderma and dermatomyositis. Characteristic feature of the disease that were found in the patient include typical skin changes, sclerodactyly, arthralgia, muscle weakness, and positive ANA with speckled pattern. After establishing the diagnosis, the patient was given emollient and sunblock for topical treatment, oral corticosteroid, and methotrexate systemic treatment. Significant clinical improvement was observed during her follow-ups.

REFERENCES

- Hoffman RW. Overlap syndromes, mixed connective tissue disease, and undifferentiated connective tissue disease. In: Tsokos GC, Gordon C, Smolen JS, editors. Systemic lupus erythematosus a companion to rheumatology. Philadelphia: Elsevier; 2007. p. 429-37.
- Jury EC, D'Cruz D, Morrow WJ. Autoantibodies and overlap syndromes in autoimmune rheumatic disease. *J ClinPathol* 2001;54:340-7.
- Jablonska S, Blaszczyk M. Scleromyositis: a scleroderma/polymyositis overlap syndrome. *ClinRheumatol* 1998;17:465-7.
- Marcus M, Ilyas M, Tolaymat A. Childhood scleromyositis with a negative PM/Scl antibody. *Joint Bone Spine* 2010;77:73-5.
- Iorizzo LJ, Jorizzo JL. The treatment and prognosis of dermatomyositis: an updated review. *J Am AcadDermatol* 2008;59:99-112.
- James WD, Berger TG, Elston DM, editors. *Andrews' diseases of the skin clinical dermatology*. 10th ed. Canada: Elsevier; 2006. p. 166-77.

7. Sontheimer RD, Costner MI. Dermatomyositis. In: Wolff K, Goldsmith LA, Katz SI, Gilchrist BA, Paller AS, Leffell DJ, editors. Fitzpatrick's dermatology in general medicine. 7th ed. New York: McGraw-Hill; 2008. p. 1536-53.
8. Sontheimer RD. The management of dermatomyositis: current treatment options. *Expert OpinPharmacother* 2004;5:1083-99.
9. Klein RQ, Teal V, Taylor L, Troxel AB, Werth VP. Number, characteristics, and classification of patients with dermatomyositis seen by dermatology and rheumatology departments at a large tertiary medical center. *J Am AcadDermatol* 2007;57:937-43.
10. Nagaraju K, Lundberg IE. Inflammatory diseases of muscle and other myopathies. In: Firestein GS, Budd RC, Harris ED, McInnes IB, Ruddy S, Sargent JS, editors. Kelley's textbook of rheumatology. 8th ed. Philadelphia: Elsevier; 2009. p.1353-78.
11. Goodfield MJD, Jones SK, Veale DJ. Connective tissue disease. In: Burns T, Breathnach S, Cox N, Griffiths C, editors. Rook's textbook of dermatology. 7th ed. Massachusetts: Blackwell Science; 2004. p. 56,91-116.
12. Hall JAM. Dermatomyositis-scleroderma overlap syndrome presenting as autoimmune haemolyticanaemia. *Rheumatology* 2002;41:956-8.
13. Jorizzo JL. Dermatomyositis. In: Bologna JL, Jorizzo JL, Rapini RP, editors. Dermatology. New York: Mosby; 2003. p. 615-22.
14. Hoffman RW. Mixed connective tissue disease and overlap syndromes. In: Wallace DJ, Hahn BH, editors. Dubois' lupus erythematosus. 7th ed. Philadelphia: Lippincott Williams & Wilkins; 2006. p. 975-87.
15. Ramos GR, Diaz VG, Tovar MG, Luna A, Diaz EA, Esparza R. A dermatomyositis and scleroderma overlap syndrome with remarkable high titer of anti-exosome antibodies. *Reumatismo* 2008;60:296-300.
16. Bennet RM. Overlap syndromes. In: Firestein GS, Budd RC, Harris ED, McInnes IB, Ruddy S, Sargent JS, editors. Kelley's textbook of rheumatology. 8th ed. Philadelphia: Elsevier; 2009. p. 1381-97.
17. Maddison PJ. Mixed connective tissue disease overlap syndromes. *Bailliere'sClinRheumatol* 2004;14(1):111-24
18. Denton CP, Black CM. Scleroderma (systemic sclerosis). In: Wolff K, Goldsmith LA, Katz SI, Gilchrist BA, Paller AS, Leffell DJ, editors. Fitzpatrick's dermatology in general medicine. 7th ed. New York: McGraw-Hill Incorporation; 2008. p. 1553-62.
19. Seibold JR. Scleroderma and mixed connective tissue diseases. In: Ruddy S, Harris ED, Sledge C, editors. Kelley's textbook of rheumatology. 6th ed. Massachusetts:W.B. Saunders Company; 2001. p. 1211-31.
20. Falanga V. Systemic sclerosis (scleroderma). In: Bologna JL, Jorizzo JL, Rapini RP, Editors. Dermatology. New York: Mosby-Year Book Incorporation; 2003. p. 625-631.
21. Winfield H, Jawrosky C. Connective Tissue Disease. In: Elder D, Elenitsas R, Johnson BL, Murphy GF, editors. Lever's histopathology of the skin. 10th ed. Philadelphia: Lippincott-Raven; 2009. p. 293-296.
22. Weedon D. Weedon's skin pathology. 3rd ed. Canada:Elsevier; 2009. p. 64-66,304-10.
23. Desai SP, Isa-Pratt S. Rheumatology. In: Clinician's guide to laboratory medicine a practical approach. Ohio: Lexi-comp Incorporation; 2000. p. 587-624.
24. Nakamura RM. Clinical and laboratory evaluation of systemic rheumatic diseases. In: Henry JB, editor. Clinical diagnosis and management by laboratory methods. 19th ed. Philadelphia: W.B. Saunders Company; 1996. p. 1013-23.
25. Sunkureddi P, Oghalai TU, Jarvis JL, Karnath BM. Signs of dermatomyositis. *Hospital Physic* 2005;7:41-4.
26. Fiorentino DF, Callen JP. Dermatomyositis. In: Williams H, Bigby M, Diepgen T, Herxheimer A, Naldi L, editors. Evidence-base dermatology. 2nd ed. Victoria: Blackwell Publishings; 2008. p. 559-70.
27. Wolverson SE. Corticosteroid and the integument. In: Lin AN, Paget SA, editors. Principles of corticosteroid therapy. New York: Arnold; 2002. p. 166-7.
28. Chen YJ, Wu CY, Huang YL, Wang CB, Shen JL, Chang TJ. Cancer risks of dermatomyositis and polymyositis: a nationwide cohort study in Taiwan. *Arthritis Research Ther* 2010;12:1-7.
29. Dalakas MC. Polymyositis, dermatomyositis, and inclusion body myositis. In: Kasper LD, Braunwald E, Fauci AS, Hauser SL, Longo DL, editors. Harrison's principles of internal medicine. 16th ed. New York: McGraw-Hill; 2005. p. 2540-5.