

Osteomalacia Induced by Renal Tubular Acidosis Type 1

Steven Sutanto Sihombing¹, Anna Ariane², RM Suryo Anggoro Kusumo Wibowo², Bambang Setyohadi²

¹Internal Medicine Residency Program, Department of Internal Medicine, Faculty of Medicine University of Indonesia, Cipto Mangunkusumo Hospital

²Rheumatology Division, Department of Internal Medicine, Faculty of Medicine University of Indonesia, Cipto Mangunkusumo Hospital

Correspondence: Steven Sutanto Sihombing, MD
Email: steven.sutanto.s@gmail.com

Abstract

Renal Tubular Acidosis, a group of disorders characterized by defective renal acid-base regulation, can impair mineralization of bone matrix in adults known as osteomalacia. RTA is classified into 3 major forms, such as proximal RTA or type 2; distal RTA or type 1; and hyperkalemic RTA or type 4. Among all type of RTA, proximal RTA or type 2 is known have association with Fanconi syndrome and bone involvement. However, distal RTA or type 1 can also cause osteomalacia. Hereby we report a case of 22 years old Asian woman who was firstly diagnosed with distal type RTA several years ago then started developing bone involvement recently. She was complaining with low back pain due to fracture on left medial side of inferior pubic ramus and endplate fracture on right side superior L4 and BMD examination showed low mineral density. She was diagnosed with osteomalacia induced by distal type RTA due to the loss of calcium salts from bone and hypophosphatemia.

Keywords: Osteomalacia; Renal Tubular Acidosis; Hypokalemia; Hypophosphatemia

Introduction

Osteomalacia is the softening of the bones due to defective mineralization of the bone organic matrices. Osteomalacia is caused by inadequate intake or malabsorption of vitamin D and/or vitamin D metabolism disorders such as in chronic renal failure. Osteomalacia can also be caused by long standing hypophosphatemia due to renal phosphate wasting or excessive use of phosphate binders. Patients with osteomalacia may complain of bone pain and have muscle weakness, pigeon chest, spinal curvature and pseudofractures.^{1,2}

Renal Tubular Acidosis (RTA) causes transport defect in the reabsorption of bicarbonate (HCO_3^-), the excretion of hydrogen ion (H^+), or both. The syndromes of RTA are characterized by relatively normal GFR and metabolic acidosis, accompanied by hyperchloremia and normal plasma anion gap.^{3,4}

RTA is classified into 3 major forms are proximal RTA or type 2, distal RTA or type 1, and hyperkalemic RTA or type 4. Proximal RTA is caused by impairment of HCO_3^- reabsorption in

proximal tubule and characterized by decreasing renal HCO_3^- threshold; distal RTA is caused by impairment of distal acidification and characterized with inability to lower urinary pH optimally under systemic acidemia condition. In general, HCO_3^- reabsorption is quantitatively normal in distal RTA. In hyperkalemic RTA (type 4), the acidification defect is caused mainly by impairment of ammoniogenesis and characterized by normal ability to acidify the urine after an acid load associated to subnormal net acid excretion due to very low rates of NH_4^+ excretion.^{3,4}

RTA has been identified as a cause of osteomalacia. Proximal RTA is RTA which associated with Fanconi syndrome and osteomalacia due to hypophosphatemia and relative 1,25-dihydroxy vitamin D deficiency but rarely rickets and osteomalacia can also be caused by distal RTA.⁵⁻¹¹

Herewith, we reported a rare case of osteomalacia induced by distal RTA in 22 years old Asian female. She was diagnosed with distal RTA two years before she complained about bone pain and eventually diagnosed with osteomalacia.

Case Report

A 22 years old female came to rheumatology clinic in Cipto Mangunkusumo National Hospital due to low back pain which has been getting worse since six month ago. She was complaining pain on her back especially when she walks far, climbs up the stairs, and during sexual intercourse. She was diagnosed with Renal Tubular Acidosis Type 1 two years ago although the first time she complained about general weakness and low level of potassium was five years ago.

Five years ago, because of general weakness, she went to nearby hospital and diagnosed as hypokalemia. She had been treated with potassium supplementation and bicarbonate for three years before she admitted to our hospital one years ago due to worsening general weakness and hypokalemia. She was diagnosed with Renal Tubular Acidosis type 1 and was given potassium chloride, potassium citrate and bicarbonate.

Table 1. Laboratory Examination Result First Time Admitted to RSCM

Laboratory Examination Result (December 2014)		
Hb	12 g/dL	Urine Examination
Ht	35%	Color: Yellow
WBC	29,790/ μ L	WBC: 5-6/hpf
Platelet	451,000/ μ L	RBC: 25-27/hpf
ESR	84mm	Cylinder : negative
Na/K/Cl (mEq/L)	140 / 2,39 / 110	Bacteria : negative
Mg (mg/dL)	1,27	BJ 1.015, pH 7.5
Ca ion (mmol/L)	0,78	Bilirubin : negative
Phosphate (mg/dL)	0,8	Albumin : negative
AST/ALT (U/L)	17 / 17	Glucose : negative
Ureum/Creatinin (mg/dL)	10 / 1,2	Keton : negative
Urine Na per 24 hours	131 mEq/24 hrs	Blood/Hb : +2
Urine K per 24 hours	85 mEq/24 hrs	Nitrite : negative
Urine Cl per 24 hours	165 mEq/24 hrs	Leucocyte esterase : negative

ABG : pH 7.108/ pCO₂ 30.10/ pO₂ 122.90/ HCO₃ 9.6/ BE -18/ SpO₂ 97%

Hb: Hemoglobin; WBC: White Blood Cells; RBC: Red Blood Cells; ESR: Erythrocyte Sedimentation Rate; AST: aspartate transaminase; ALT: alanine transaminase; ABG: Analysis Blood Gas

Although she was routinely went to our nephrology clinic in Cipto Mangunkusumo National Hospital, she still had recurrent symptoms of generalized weakness and hypokalemia due to lack of potassium citrate available in pharmacies.

From the kidney ultrasonography examination by nephrologist, there was nephroclacnosis bilateral with mutiple cyst in right kidney. She started complaining about low back pain since 6 months ago when she was walking far away, climbing up stairs, bending over and during sexual intercourse with her husband. Due to the worsening of the back pain, she was suggested to do lumbar and pelvic X-ray examination. X-ray photos showed fracture on left medial side of inferior pubic ramus and suspected fracture on right inferior pubic ramus and superior pubic ramus. There is also endplate fracture on right side superior L4 spine.

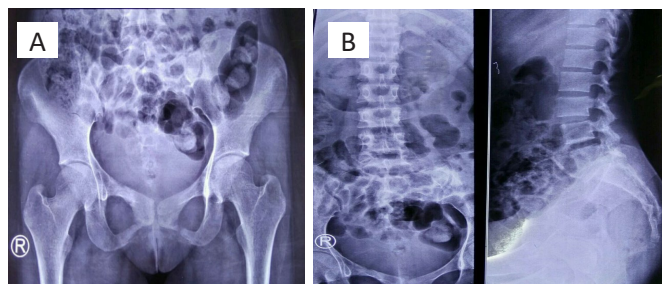


Figure 1. A. Pelvic X-Ray Examination showed fracture on left medial side of inferior pubic ramus. B. Lumbar X-Ray Examination showed endplate fracture on right side superior L4

She was referred to rheumatology clinic due to suspected bone and mineral disorder. She was examined for alkaline

phosphatase and parathyroid hormone in serum, also calcium and phosphate level in urin. She had low level of calcium and phosphate in urine and high level of intact parathyroid hormone.

Table 2. Laboratory Examination Result From Rheumatology Clinic

Laboratory Examination Result (March 2017)	
Alkaline Phosphatase	358 U/L (high)
Urin calcium	2.6 mg/dL
Urin calcium 24 hours	45.5 mg/24 hrs (low)
Urin Inorganic Phosphate	0.3 g/24 hrs (low)
Urine volume	1750 mL
Phosphate	1.4 mg/dL (low)
Ureum	23 mg/dL
Creatinin	0.8 mg/dL

ABG : pH 7.317/ pCO₂ 29.7/ pO₂ 96.40/ HCO₃ 15.30/ BE -8.60/ SpO₂ 97%

ABG: Analysis Blood Gas, BE: Base Excess.

Beside laboratory work up, she was also examined for bone mineral density (BMD). Her BMD examination showed low mineral density with Z score L1-4: -2.2 and Z score radius 33%: -1.5.

Table 3. Bone Mineral Density Examination Result

Region	BMD (g/cm ²)	Young-Adult		Age-Matched	
		(%)	T-score	(%)	Z-score
L1	0.757	72	-2.4	79	-1.7
L2	0.783	70	-2.8	76	-2.1
L3	0.798	70	-2.8	76	-2.1
L4	0.740	65	-3.3	71	-2.6
L1-L2	0.771	71	-2.6	77	-1.9
L1-L3	0.781	71	-2.7	77	-2.0
L1-L4	0.768	69	-2.9	75	-2.2
L2-L3	0.791	70	-2.8	76	-2.1
L2-L4	0.771	68	-3.0	74	-2.3
L3-L4	0.767	68	-3.1	73	-2.4
Neck	0.688	75	-1.9	78	-1.6
Wards	0.594	68	-2.0	70	-1.8
Troch	0.505	67	-2.3	71	-1.8
Shaft	0.774	-	-	-	-
Total	0.641	67	-2.5	71	-2.1
Radius UD	0.293	65	-3.4	65	-3.4
Ulna UD	0.226	-	-	-	-
Radius 33%	0.716	84	-1.5	84	-1.5
Ulna 33%	0.760	-	-	-	-
Both UD	0.269	-	-	-	-
Both 33%	0.736	-	-	-	-
Radius Total	0.535	81	-2.0	81	-2.0
Ulna Total	0.521	-	-	-	-
Both Total	0.529	-	-	-	-

Based on the examination results, she was diagnosed with osteomalacia induced by renal tubular acidosis type 1 and also secondary hyperparathyroidism.

Discussion

Renal Tubular Acidosis type I is caused by impaired distal acidification and is characterized by inability to lower urinary pH maximally (pH <5.5) under the stimulus of systemic acidemia. In general, HCO₃⁻ reabsorption is quantitatively normal.³

Soriano, et al. tried to simplify the difference between various type of RTA in a table. From that table we can conclude that our patients fit into distal RTA (type 1) due to decreased plasma K⁺, positive urinary anion gap (urinary Na plus K level per 24 hours is bigger than urinary chloride level), urine pH > 5.5 and also presence of nephrocalcinosis. Ca excretion usually increased in distal RTA but it was decreased in our case. We need to remember that our patient has already been treated with potassium chloride and bicarbonate for three years before she was admitted to our hospital.³

Table 4. Differential Diagnosis of Various Type of RTA³

	Proximal RTA (type 2)	Distal RTA (type 1)			Hyperkalemic RTA (type 4)
		"Classic"	With HCO ₃ ⁻ Wasting (type 3)	Hyperkalemic	
In situation of metabolic acidosis (spontaneously or after acid loading)					
plasma K ⁺	N or D	N or D	N or D	I	I
urinary anion gap	Negative	Positive	Positive	Positive	Positive
urine pH	<5.5	>5.5	>5.5	>5.5	<5.5
NH ₄ ⁺ excretion	N	D	D	D	D
fractional K ⁺ excretion	N or I	I	I	D	D
Ca excretion	N	I	I	I	N or D
citrate excretion	N	D	D	D	N
In situation of normal acid-base equilibrium (after alkali loading)					
fractional HCO ₃ ⁻ excretion	>10 to 15%	<5%	>5 to 15%	<5%	>5 to 10%
U-B Pco ₂	>20 mmHg	<20 mmHg	<20 mmHg	>20 mmHg	>20 mmHg
Other tubular defects	Often present	Absent	Absent	Absent	Absent
Nephrocalcinosis/lithiasis	Absent	Often present	Often present	Often present	Absent
Bone involvement	Often present	Rarely present	Rarely present	Rarely present	Absent

* N, normal; I, increased; D, decreased.

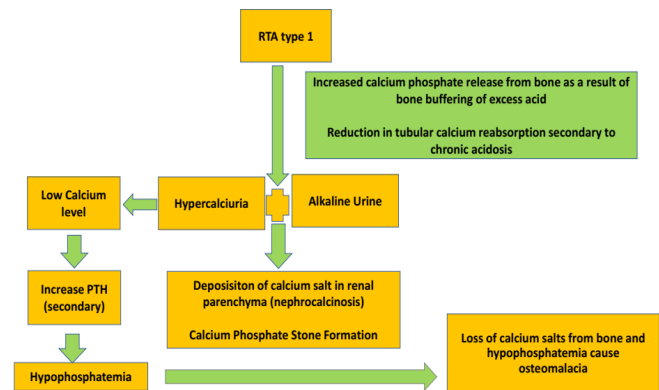
Our patient also has bone involvement which is more common in proximal RTA than distal RTA. She had fracture on left medial side of inferior pubic ramus and suspected fracture on right inferior pubic ramus and superior pubic ramus. There is also an endplate fracture on right side superior L4 and low mineral density in BMD examination. According to the International Society for Clinical Densitometry, for premenopausal women Z scores of -2.0 or less are below the expected range for age.¹²

Distal RTA or RTA type 1 can induced osteomalacia, although not as common as proximal RTA or RTA type 2. In RTA type 1, there is an increased calcium phosphate release from bone as a result of bone buffering in the excess acid condition. Besides, there is also reduction in tubular calcium reabsorption secondary to chronic acidosis. Those will lead to hypercalciuria and alkaline urine which increased deposition of calcium salt in renal parenchyma (nephrocalcinosis) and

also induce calcium phosphate stone formation.

Low calcium serum level can increase parathyroid hormone just like what happened in our patient. The hyperparathyroidism can increased renal phosphate excretion which lead to hypophosphatemia due to the ability of parathyroid hormone in inhibiting proximal renal tubule phosphate transport. Our patient has low level of calcium and phosphate in serum although the excretion in the urine was also decreased. Loss of calcium salts from bone and hypophosphatemia in our patient can result in osteomalacia. The pathogenesis of RTA type 1 is presented in Figure 2.

Figure 2. Pathogenesis Osteomalacia Induced by RTA type 1



Conclusion

RTA has been identified to cause osteomalacia in adults. Bone involvement is more common in proximal type RTA (type 2) but distal RTA (type 1) can also cause osteomalacia due to loss of calcium salts from bone and hypophosphatemia.

References

1. Longo DL, Fauci AS, Kasper DL, Hauser SL, Jameson JL, Loscalzo J. Harrison's Manual Of Medicine, 18th Edition. United States: McGraw Hill; 2013
2. Fukumoto S, Ozono K, Michigami T, et al. Pathogenesis and diagnostic criteria for rickets and osteomalacia-Proposal by an expert panel supported by Ministry of Health, Labour and Welfare, Japan, The Japanese Society for Bone and Mineral Research and The Japan Endocrine Society. Endocrine Journal. 2015; 62(8) : 665-671
3. Soriano JR. Renal Tubular Acidosis: The Clinical Entity. J Am Soc Nephrol. 2002; 13: 2160-2170
4. Yaxley J, Pirrone C. Review of the Diagnostic Evaluation of Renal Tubular Acidosis. Ochsner J. 2016; 16(4) : 525-530
5. Clarke BL, Wynne AG, Wilson DM, Fitzpatrick LA. Osteomalacia associated with adult Fanconi's syndrome: clinical and diagnostic features. Clinical Endocrinology. 1995; 43(4): 479-490
6. Taylor HC, Elbadavy EH. Renal tubular acidosis type 2 with Fanconi's syndrome, osteomalacia, osteoporosis, and secondary hyperaldosteronism in an adult consequent to vitamin D and calcium deficiency: effect of vitamin D and calcium citrate therapy. Endocr Pract. 2006; 12(5):559-67
7. Ali Y, Parekh A, Baig M, Ali T, Rafiq T. Renal tubular acidosis type II associated with vitamin D deficiency presenting as chronic weakness. Ther Adv Endocrinol Metab. 2014;5(4): 86-89

8. Yamaguchi S, Maruyama T, Wakino S, et al. A case of severe osteomalacia caused by Tubulointerstitial nephritis with Fanconi syndrome in asymptomatic primary billiary cirrhosis. *BMC Nephrology*. 2015;16 : 187
9. Lee JH, Park JH, Ha TS, Han HS. Refractory rickets caused by mild distal renal tubular acidosis. *Ann Pediatr Endocrinol Metab*. 2013; 18(3): 152-155
10. Haridas V, Haridas K, Mudrabettu C. Case Studies : Renal tubular acidosis presenting as osteomalacia. *Internet Journal of Rheumatology an Clinical Immunology*. 2017;(5):1:CS2
11. Tahir M, Ansari JK. Osteomalacia Due To Type-1 Renal Tubular Acidosis In A Middle Aged Pakistani Woman. *PAFMI*. 2009;50(1): 123-125
12. Jeremiah MP, Unwin BK, Greenwald MH. Diagnosis and Management and Management of Osteoporosis. *Am Fam Physician*. 2015; 92(4):261-268