

# Osteoarticular Tuberculosis: A Secondary Manifestations to Tuberculous Pleural Effusion

Gurmeet Singh<sup>1</sup>, Cleopas M Rumende<sup>1</sup>, Bambang Setyohadi<sup>2</sup>

<sup>1</sup> Division of Respiriology and Critical Illness, Departement Of Internal Medicine, University of Indonesia, Cipto Mangunkusumo Hospital

<sup>2</sup> Division of Rheumatology, Departement Of Internal Medicine, University of Indonesia, Cipto Mangunkusumo Hospital

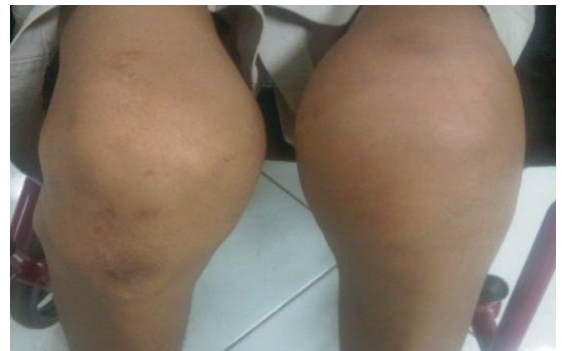Tuberculosis appears to be increasing throughout the world after years of continuous decline, despite the introduction of effective chemotherapy. This resurgence is related to the increasing number of patients immunocompromised by chemotherapeutic agents used to treat other diseases or Acquired Immunodeficiency Syndrome (AIDS); the appearance of multiple drug-resistant strains of tuberculosis, and aging population. Musculoskeletal tuberculosis arises from haematogenous seeding of the bacilli soon after the initial pulmonary infection.<sup>1</sup> Osteoarticular TB can occur in the knee - one study found of 1074 cases, 8.3 percent - or 90 cases - affected the knee.<sup>2</sup> The clinical symptoms are insidious onset, pain, swelling of the joint and limited range of movements. Investigations for suspected cases include: Mantoux test, radiological imaging, fine needle aspiration biopsy, surgical biopsy, bacteriological examination, histopathological examination, and polymerase chain reaction (PCR) of a suitable specimen. The mainstay of treatment is multidrug antitubercular chemotherapy. The main reason for poor outcome is delayed diagnosis.<sup>1</sup>

We report a case of osteoarticular manifestation of tuberculosis infection affecting the left knee presenting in a man with a history of tuberculosis pleural effusion. This case highlights, firstly, osteoarticular disease is always secondary to a primary lesion in the lung and, secondly, the diagnosis of tubercular arthritis can be challenging, particularly in the presence of confounding factors such as preexisting arthritis. Ethical approval was not required for this case study.

## Case Report

A 22-year old man, presented to the rheumatology clinic with a painful and swollen left knee. His symptoms had gradually worsened over a period of one month whereby now he had a limited range of movement of the knee. The symptoms dated from a fall 1 month previously. The patient reported symptoms of respiratory infections. He denied any intravenous drug use or HIV risk factors and had good immune status. He recalled history of tuberculosis year ago and was on antitubercular treatment for 2 weeks (stop on his own due too abdominal symptoms). The initial physical examination revealed tachycardia (110 beats/minute), fever (38°C), arthritis of the left

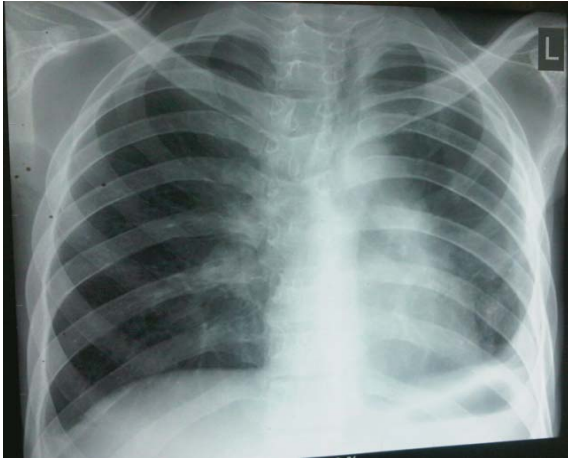
knee and low Body Mass Index (BMI)16.5 kg/m<sup>2</sup>. Lung auscultation revealed signs of moderate rales. Examination of the left knee revealed a swollen warm knee, painful, restricted with reduced flexion ability and small amounts of effusion in the left knee joints (Figure 1).



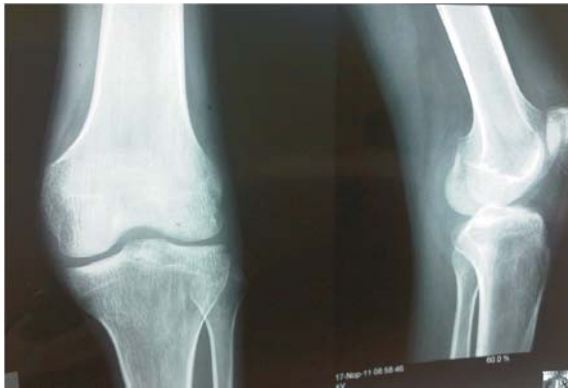**Figure 1.** Physical examination revealed painful swelling of the left knee

Automated blood counts demonstrated a total white cell count of  $13.37 \times 10^3/L$ , neutrophil segment of 91%, an erythrocyte sedimentation rate prolonged to 35 mm/hr and hypoalbuminemia (3.0g/dl). Sputum smears for AFB were negative. Chest radiography revealed infiltrates and pleural effusions of the left lung (Figure 2). On plain radiography, the affected knee appeared normal other than subtle soft tissue swelling (Figure 3). Patient underwent arthrocentesis of the left knee and a total of 4 mL of cloudy yellowish-coloured fluid was removed and sent for PCR, culture and microscopy. Culture yielded negative results, PCR was positive for M. TB, and no crystals were seen. Culture for acid-fast bacilli was not requested (lack of fluid sample). We concluded that this patient suffered from an acute monoarthritis due to osteoarticular tuberculosis. Patient reject for thoracocentesis and hospitalization. Antibiotic were given for respiratory infection symptoms and a referral was arranged to the hospital's tuberculosis clinic. A decision was made to start antitubercular treatment with isoniazid, rifampicin, pyrazinamide and ethambutol pending the culture results. The patient left against medical advice several hours later. Respiratory symptoms disappeared in a week under antibiotics. After 6 weeks of treatment, the patient showed improvement in his general health as well as reduction in the left knee swelling. At

the time of writing, he was continuing to follow up as an outpatient at the tuberculosis clinic.



**Figure 2.** Chest radiograph showing parapneumonic pleural effusion



**Figure 3.** Anteroposterior and lateral radiographs of the knee showing is unremarkable other than a subtle soft-tissue swelling

**Discussion**

It is estimated that there are nine million people worldwide infected with the active form of TB and it is the direct cause of around two million deaths per year.<sup>3</sup> Tuberculosis is typically classified as pulmonary or extrapulmonary. About 60% of cases are pulmonary, and of the remainder about 7% involve bone or joints or both. Tuberculous arthritis is usually monoarthritis with a predilection for weight-bearing joints; however, up to 15% of cases are polyarticular.<sup>4</sup> In adults, TB shows a preponderance to the spine (40%), then the hip (25%), and finally the knee (8%).<sup>5,6</sup> While extrapulmonary manifestations of TB are common, accounting for around 15–20% of cases in immunocompetent patients, the first presentation of the disease as a joint infection is rare.<sup>7</sup> Primary bone infection with TB is less likely than hematogenous spread from a primary focus elsewhere.<sup>3</sup> Musculoskeletal tuberculosis arises from hematogenous seeding of the bacilli soon after the initial pulmonary infection.<sup>4</sup> Although, our patient showed respiratory symptoms, the rest of the symptoms were actually typical clinical initiation of specific synovitis of the knee: fever and painful swelling of the joint.

Culture of synovial fluid gives positive results in 79% of cases, but synovial biopsy may be required to grow the organism. In some cases the organism will not be seen on smear

or culture, but caseating granulomas will be demonstrated on histologic examination. For this reason histologic studies must be performed in cases in which microbiologic tests give negative results in order to confidently exclude tuberculosis as a cause of chronic arthritis. In our case, sputum smears for AFB were negative and PCR of the joint fluid confirmed the diagnosis. Plain radiographic findings of tuberculous arthritis are only seen after a latent period of about 3-4 weeks. Joint effusion and soft-tissue swelling are the only findings in early stages. In the late stages, the classic ‘Phemister triad’ of joint space reduction, juxta-articular osteoporosis and peripheral osseous erosions are described. Early changes are better demonstrated on MRI which has now become the mainstay of imaging in musculoskeletal tuberculosis.<sup>8</sup> Options for treatment once the diagnosis is confirmed must involve antituberculous chemotherapy, but surgery may be indicated to improve symptoms and quality of life in patients affected by joint infection. Unlike for pulmonary TB, the treatment for bone and joint disease is a lengthier process, often requiring twelve to eighteen months of chemotherapy.<sup>9,10</sup>

**Conclusion**

Any case of acute arthritis is septic until proven otherwise, and any case of chronic arthritis ought to raise the suspicion of tuberculosis, particularly in a person from an endemic region. It remains a controversial topic whether one can ever truly describe a case of primary tuberculosis of a joint; however, there are cases, such as that presented here, which seem to manifest only as secondary manifestation to pulmonary tuberculosis.

**Acknowledgments**

The author would like to thank dr. Fanny Oktarina and the patient for the assistance in the management of the clinical case and his kind permission to report this case.

**REFERENCES**

1. Abdul H, Mousa L. Bones and Joints Tuberculosis. Bahrain Medical Bulletin, 2007;29:1-8.
2. Demni K. Tuberculosis of the Patella in Children - Case Report. Journal of Orthopedics, 2007;3:23.
3. Lidder S, Lang K, Haroon M, Shahidi M, Guindi ME. Tuberculosis of the knee. Orthop Rev (Pavia), 2009;1:24.
4. Payne K, Yang J. Osteoarticular tuberculosis: a case report and discussion. CMAJ, 2002;5:628-30.
5. Mittal R, Trikha V, Rastogi S. Tuberculosis of patella. The Knee, 2006;13:54–6.
6. Adler AC. Tuberculosis: Old World treatment for New World disease. Clin Imaging, 2009;33:136.
7. Sharma SK, Mohan A. Extrapulmonary tuberculosis. Indian J Med Res, 2004;120:316-53.
8. Mah ESL, Bux SI. Tuberculous synovitis of the knee with unusually thick synovial granulation tissue: A Case Report. The Internet Journal of Orthopedic Surgery, 2007;2:1531-2968.
9. Vaughan KD. Extrapulmonary osteoarticular tuberculosis: A forgotten entity? West Indian Med J, 2005;54:202–6.
10. Leclere LE, Sechriest VF, Holley KG. Tuberculous arthritis of the knee treated with two-stage total knee arthroplasty. A case report. J Bone Joint Surg (Am), 2009;91:186–91.